

## When Waiting Saves Myocardium: Deferred stenting in a 30-year-old STEMI Patient

Astri Meliana<sup>1</sup>, I Putu Gede Budiana<sup>2</sup>, I Dewa Agung Gede Oka Dwi Wicaksana<sup>3</sup>

<sup>1,3</sup> General Practitioner, Mangusada Hospital, Badung, Bali, Indonesia

<sup>2</sup> Departement of Cardiology and Vascular Medicine, Mangusada Hospital, Badung, Bali, Indonesia

\*Corresponding Author: astrimeliana111@gmail.com

**Abstract:** Acute coronary syndrome (ACS) is one of the manifestations of cardiovascular disease (CVD) that often occurs in patients. The ST-elevation myocardial infarction (STEMI) was the most common of ACS manifestations and showed high mortality rates. Therefore, adequate treatment is required. The primary PCI remains a gold standard in STEMI management, as it significantly improves clinical outcomes by restoring coronary blood flow and preserving jeopardized myocardium.

A 30-year-old male patient presented with chest pain 5 hours ago. The pain was located in the mid-sternal area of the chest and radiated to the back. The symptoms developed after the patient had finished playing futsal. The patient denied other associated symptoms such as shortness of breath. The ECG showed ST-elevation in V1-V6 leads and high hs-troponin marker. The patient was diagnosed with an extensive anterior ST-elevation myocardial infarction. On coronary angiography examination, the patient was resulted with high thrombus burden. Moreover, the patient was treated with initial pharmacological medications and primary PCI, particularly the plain old balloon angioplasty (POBA) with deferred stenting. On the sixth day of hospitalization, the patient had a stable condition and was discharged from the hospital.

The primary PCI with POBA and deferred stenting can be considered as an alternative treatment approach in STEMI with HTB patients.

**Keywords:** STEMI, HTB, PCI, deferred stenting

**Abstrak:** Sindrom koroner akut (Acute Coronary Syndrome/ACS) merupakan salah satu manifestasi penyakit kardiovaskular yang sering ditemukan dan menjadi penyebab utama morbiditas serta mortalitas global. Infark miokard dengan elevasi segmen ST (ST-Elevation Myocardial Infarction/STEMI) merupakan bentuk ACS yang paling sering dengan risiko kematian tinggi sehingga memerlukan penanganan segera dan tepat. Primary percutaneous coronary intervention (primary PCI) merupakan standar emas dalam tatalaksana STEMI karena terbukti mampu memperbaiki luaran klinis dengan cara memulihkan aliran darah koroner dan menyelamatkan miokard yang masih viable. Laporan kasus ini menggambarkan seorang pasien laki-laki berusia 30 tahun yang datang dengan keluhan nyeri dada sejak 5 jam sebelum masuk rumah sakit. Nyeri dirasakan di area substernal dan menjalar ke punggung setelah aktivitas fisik bermain futsal. Pasien tidak mengeluhkan sesak napas. Pemeriksaan elektrokardiografi menunjukkan elevasi segmen ST pada sadapan V1-V6 disertai peningkatan kadar hs-troponin, sehingga pasien didiagnosis sebagai infark miokard akut STEMI anterior ekstensif. Hasil angiografi koroner menunjukkan adanya beban trombus yang tinggi (high thrombus burden/HTB). Pasien kemudian mendapatkan terapi farmakologis awal dan tindakan primary PCI berupa plain old balloon angioplasty (POBA) dengan strategi deferred stenting. Selama perawatan, kondisi klinis pasien membaik dan stabil, serta pada hari ke-6 pasien diperbolehkan pulang. Kesimpulannya, primary PCI dengan POBA dan deferred stenting dapat dipertimbangkan sebagai alternatif strategi terapi pada kasus STEMI dengan high thrombus burden.

**Kata kunci:** STEMI, high thrombus burden, PCI, deferred stenting

### Introduction

Acute coronary syndrome (ACS) is one of the manifestations of cardiovascular disease (CVD) that often occurs in patients. This condition is characterized by the presence of chest pain associated with recent changes in clinical signs and symptoms, with or absence of ECG 12-lead abnormalities, with or without the acute elevation of cardiac marker (troponin) levels. Furthermore, the ACS can be classified into three sections, including ST-elevation myocardial infarction (STEMI),

non-ST-elevation myocardial infarction (NSTEMI), and unstable angina (Kumar & Cannon, 2009; Elendu et al., 2023).

Based on the one ACS registry, STEMI accounts for 48.8% of acute coronary syndrome (ACS) cases, while non-ST-elevation myocardial infarction (NSTEMI) comprises 51.2%. Notably, the mortality rate among patients with STEMI is considerably higher than that observed in NSTEMI patients (11.7% vs. 6.2%) (Laksono & Nurbaeti, 2025; Kumar & Cannon, 2009). Among all types of STEMI, the anterior STEMI was known to be associated with the poorest prognosis among infarct locations, primarily due to the larger infarct size and greater release of cardiac biomarkers (Ferrante et al., 2021). Patients with anterior STEMI tend to have a more complicated clinical course, both during hospitalization and follow-up, and are at increased risk of adverse structural remodeling, including regional dilatation and thinning of the infarcted myocardium. With these high mortality rates and poorer clinical outcomes, adequate treatment is required for the patients (Ferrante et al., 2021).

According to the previous study, the initial management that can be given to the STEMI patients is reperfusion therapy. The reperfusion therapy consisted of fibrinolytics and primary percutaneous coronary intervention (Kardiovaskular PDS, 2024; Kumar & Cannon, 2009). Recent studies showed that primary percutaneous coronary intervention (PCI) is considered the standard of care for patients presenting with acute ST-elevation myocardial infarction (STEMI), as it significantly improves clinical outcomes by restoring coronary blood flow and preserving jeopardized myocardium (Satrijo, 2022; Rao et al., 2025).

Our case report focused on a patient who experienced an acute myocardial infarction with the ECG appearance revealing extensive anterior ST-segment elevation and was treated with primary PCI, particularly underwent the plain old balloon angioplasty (POBA) with deferred stenting (Pradhan et al., 2021; Hammad et al., 2025).

## **Case Presentation**

### **History**

A 30-year-old male patient came to the emergency department on February 2<sup>nd</sup>, 2026 with a chief complaint of chest pain 5 hours ago. The pain was described as a heavy, pressure-like sensation located in the mid-sternal area of the chest. The discomfort radiated to the back. At early onset of the pain, the patient also experienced an episode of vomiting. The symptoms developed after the patient had finished playing futsal. The patient denied other associated symptoms such as shortness of breath.

### **Past Medical History**

The history of diabetes mellitus, hypertension, and coronary heart disease is denied. On social history, the patient is an active smoker who smokes electronic cigarettes (vaping) and conventional cigarettes.

### Physical Examination

On vital signs examinations, the blood pressure was 120/80 mmHg, and his pulse rate was 90 beats per minute. The respiratory rate was 20 breaths per minute, and the temperature was 36.6 °C. There was no abnormalities shown in physical examination.

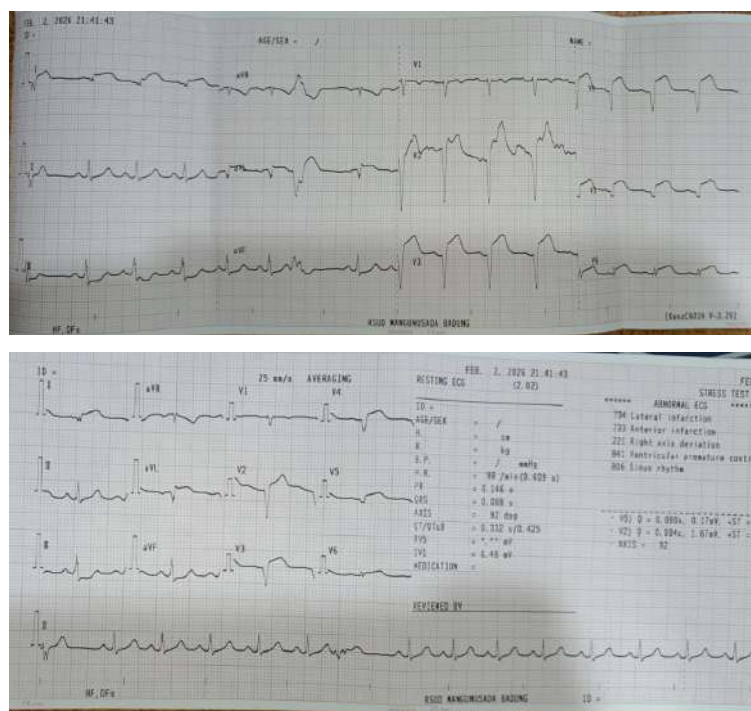
### Investigation

On emergency department, the patient had laboratory investigation and showed an increase of neutrophil count ( $17.1 \times 10^3/\mu\text{L}$ ), neutrophil-to-lymphocyte ratio (NLR) (15.5), random blood glucose (142 mg/dl), and increase of hs-Troponin-I levels (3878.9 ng/L).

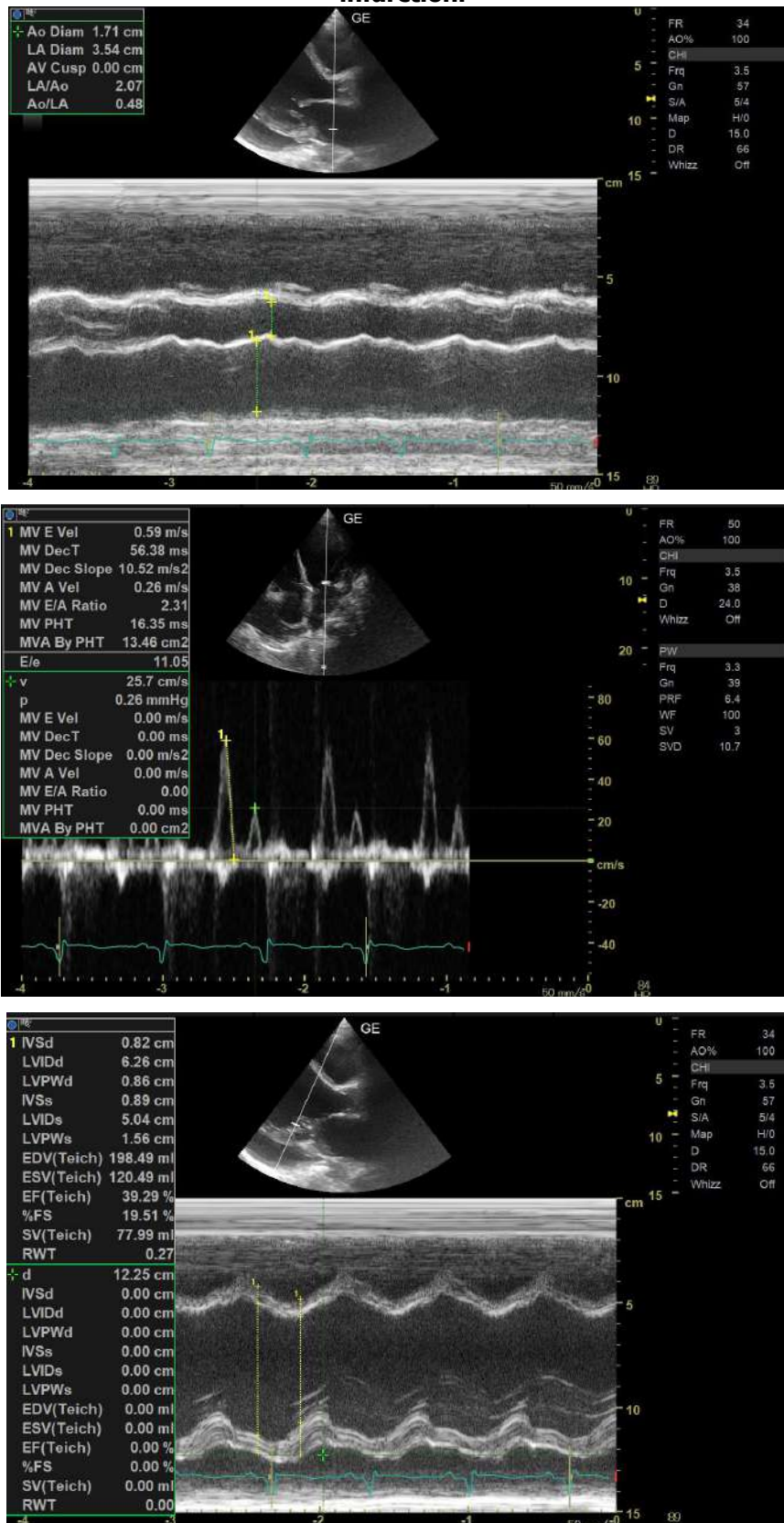
On electrocardiogram (ECG) examination, the patient showed sinus rhythm, 98 beats per minute, normal axis, ST-segment elevation in lead V1-V6 with the impression of extensive STEMI anterior (Figure 1).

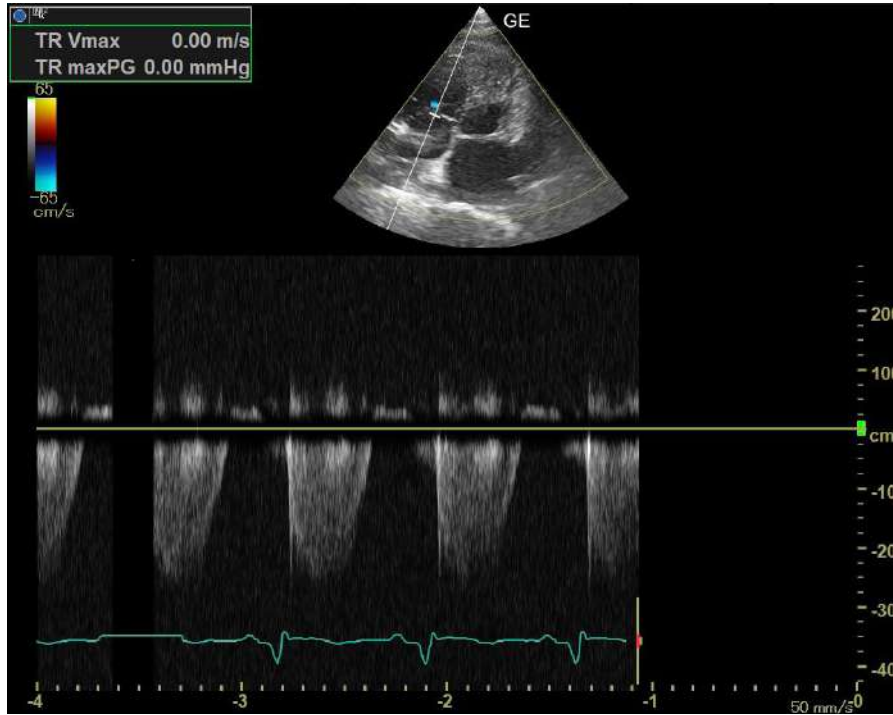Patient also underwent the echocardiography and showed RWMA (+), moderate loculated pericardial effusion at superior right atrium, inferior and lateral left ventricular. This patient also showed reduced left ventricular (LV) systolic function, and grade III left ventricular (LV) diastolic dysfunction.

The coronary angiography was conducted and showed 80-90% stenosis in the ostial to proximal in LAD, a high thrombus burden with TIMI 2-3 flow, and no bleeding was occurred.

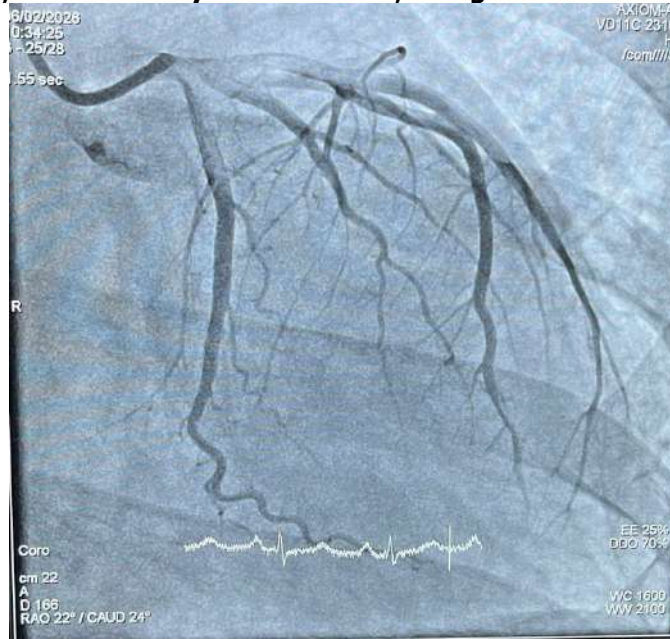

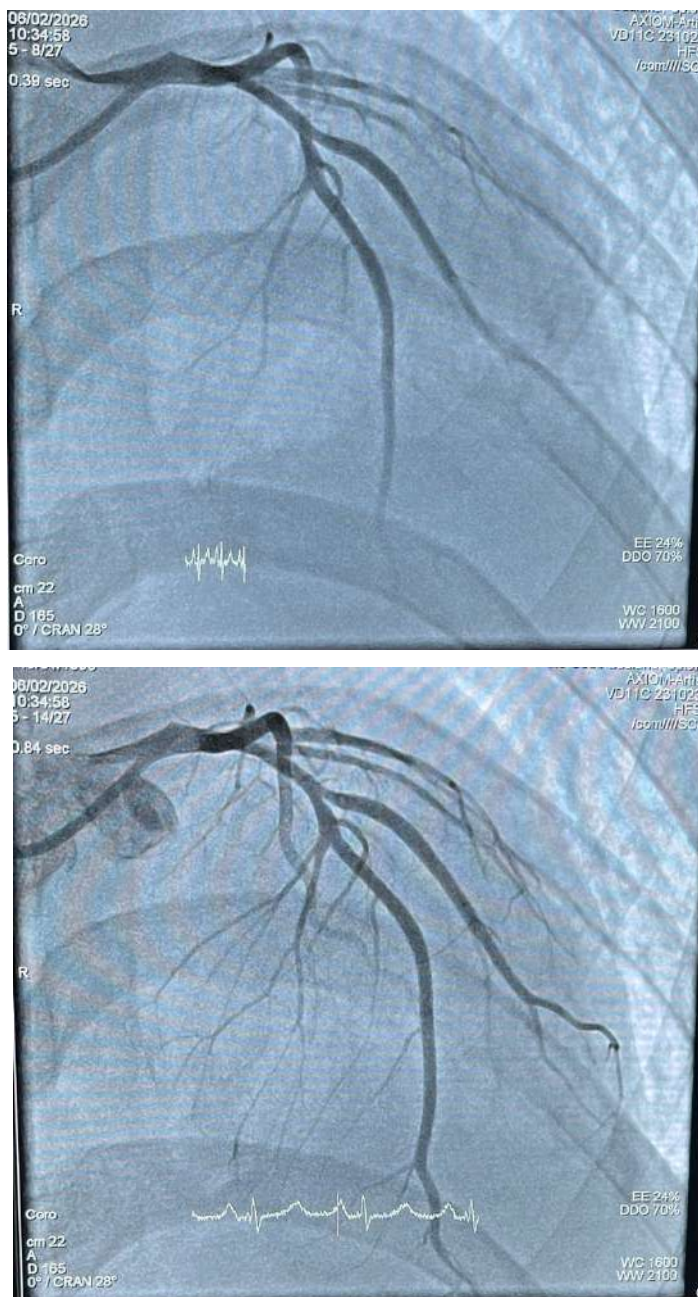**Figure 1. ECG examination showing Extensive Anterior ST-elevation myocardial infarction.**





**Figure 2. Echocardiography examination showed RWMA (+), moderate loculated pericardial effusion, reduced LV systolic function, and grade III diastolic dysfunction.**





**Figure 3. The coronary angiography (CAG) showed 80-90% stenosis in the ostial to proximal in LAD, a high thrombus burden with TIMI 2-3 flow, and no bleeding was occurred.**

**Table 1. Complete blood count test (in Emergency Department)**

Parameter	Result	Unit	Reference value	Remarks
HGB	14.6	g/dL	13.2-17.3	Normal
HCT	42.3%	%	40.0-52.0	Normal

<b>WBC</b>	<b>18.43</b>	<b>10<sup>3</sup>/uL</b>	<b>3.80-10.60</b>	<b>High</b>
PLT	262	10 <sup>3</sup> /uL	150-440	Normal
RBC	5.08	10 <sup>6</sup> /uL	4.40-5.90	Normal
MCV	83.3	fL	80.0-100.00	Normal
MCH	28.7	pg	26.00-34.00	Normal
MCHC	34.5	g/dl	32.0-36.0	Normal
PDW	9.0	fL	9.0-17.0	Normal
RDW-CV	11.7	%	11.5-14.5	Normal
<b>RDW-SD</b>	<b>35.5</b>	<b>fL</b>	<b>37.0-54.0</b>	<b>Low</b>
MPV	9.1	fL	9.0-13.0	Normal
Bas%	0.2	%	0.0-1.0	Normal
Lym%	5.7	%	25.0-40.0	Normal
<b>Mon%</b>	<b>1.4</b>	<b>%</b>	<b>2.0-8.0</b>	<b>Low</b>
<b>Neu%</b>	<b>92.6</b>	<b>%</b>	<b>50.0-70.0</b>	<b>High</b>
<b>Eos%</b>	<b>0.1</b>	<b>%</b>	<b>2.0-4.0</b>	<b>Low</b>
IG	0.4	%		
Bas#	0.0	10 <sup>3</sup> /uL	0.0-0.1	Normal
Lym#	1.1	10 <sup>3</sup> /uL	1.0-3.7	Normal
Mon#	0.30	10 <sup>3</sup> /uL	0.0-0.7	Normal
<b>Neu#</b>	<b>17.1</b>	<b>10<sup>3</sup>/uL</b>	<b>1.5-7.0</b>	<b>High</b>
Eos#	0.0	10 <sup>3</sup> /uL	0.0-0.4	Normal
IG#	0.1			
<b>NLR</b>	<b>15.5</b>		<b>≤3.13</b>	<b>High</b>

**Table 2. Clinical Chemistry Test**

Parameter	Result	Unit	Reference value	Remarks
<b>Random Blood Glucose</b>	<b>142</b>	<b>mg/dL</b>	<b>70-140</b>	<b>High</b>
<b>Cardiology Marker</b>				
<b>Hs-troponin-I</b>	<b>3878</b>	<b>ng/L</b>	<b>&lt;19</b>	<b>High</b>
<b>Renal Physiology</b>				
Ureum	32	mg/dL	15-45	Normal
Creatinine	1.0	mg/dL	0.70-1.20	Normal
eGFR (CKD-EPI)	101	mL/min/1.73 m <sup>2</sup>		
<b>Electrolyte</b>				
Natrium	144	mmol/L	136-145	
Kalium	3.8	mmol/L	3.5-5.1	
Chloride	107	mmol/L	94-110	

**Table 3. Electrolyte and Blood Gas Analysis (ICCU)**

Parameter	Result	Unit	Reference value	Remarks
pH	7.364		7.350-7.450	Normal
pCO <sub>2</sub>	35.3	mmHg	35.0-45.0	Normal
PO <sub>2</sub>	90	mmHg	80-100	Normal
<b>BE ecf</b>	<b>-6</b>	<b>mmol/L</b>	<b>(-2) – (+2)</b>	<b>Low</b>
<b>HCO<sub>3</sub></b>	<b>20.1</b>	<b>mmol/L</b>	<b>23.0-26.0</b>	<b>Low</b>
<b>Total CO<sub>2</sub></b>	<b>21.2</b>	<b>mmol/L</b>	<b>24.0-30.0</b>	<b>Low</b>
SO <sub>2</sub>	96.7	%	95-99	Normal

**Table 4. Coagulation, Lipid Profile, and Renal Physiology in ICCU (February 3<sup>rd</sup>, 2026)**

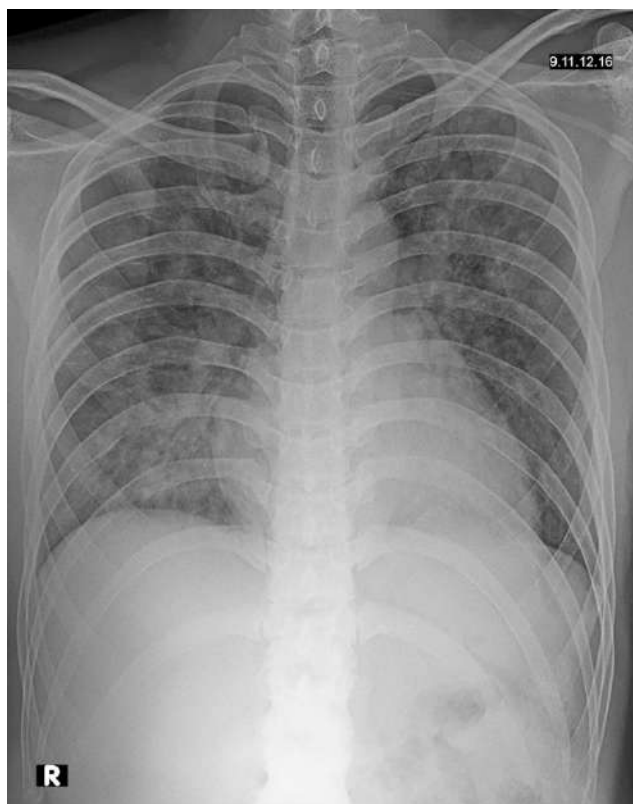Parameter	Result	Unit	Reference value	Remarks
<b>PT</b>	<b>11.6</b>	<b>seconds</b>	<b>9.3-11/4</b>	<b>High</b>
INR	1.03		0.90-1.10	
APTT	24.4	seconds	21.8-28.0	
<b>Lipid Profile</b>				
<b>HDL-cholesterol</b>	<b>31</b>	<b>mg/dL</b>	<b>35-60</b>	<b>Low</b>

Triglyceride	143	mg/dL	<150	
<b>LDL-cholesterol</b>	<b>153</b>	<b>mg/dL</b>	<b>&lt;130</b>	<b>High</b>
<b>Renal Physiology</b>				
Ureum	32	mg/dL	15-45	Normal
Creatinine	1.0	mg/dL	0.70-1.20	Normal
eGFR (CKD-EPI)	101	mL/min/1.73 m <sup>2</sup>		
<b>Uric Acid</b>	<b>9.2</b>	<b>mg/dL</b>	<b>2.0-7.0</b>	<b>High</b>

**Table 5. Renal Physiology Examination in Cardiac Unit (February 7<sup>th</sup>, 2026)**

<b>Renal Physiology</b>				
<b>Parameter</b>	<b>Result</b>	<b>Unit</b>	<b>Reference value</b>	<b>Remarks</b>
Ureum	30	mg/dL	15-45	Normal
Creatinine	1.0	mg/dL	0.70-1.20	Normal
eGFR (CKD-EPI)	101	mL/min/1.73 m <sup>2</sup>		

The patient underwent the thorax X-ray examination and showed pneumonia, which can be seen below.



**Figure 2. Thorax x-ray examination**

## **Management**

After thorough examination, the patient was diagnosed with STEMI anterior extensive. The patient was treated with intravenous fluid therapy with 0.9% NaCl administered at 8 drops/minute. Antiplatelet therapy was initiated with acetosal (aspirin) 200 mg as a loading dose, followed by 100 mg once daily, and clopidogrel 300 mg loading dose followed by 75 mg once daily. The patient was also given atorvastatin 80 mg once daily.

Additional medications included ramipril 2.5 mg once daily, isosorbide dinitrate (ISDN) 5 mg three times daily, and intravenous lansoprazole 30 mg once daily. Anticoagulation was given with enoxaparin 0.3 mL intravenously as an initial dose, followed by 0.6 mL subcutaneously twice daily.

The patient was also advised to undergo primary percutaneous coronary intervention (primary PCI) for cardiac catheterization. The patient's family was informed about the procedure, and the family agreed to do the primary PCI. After the primary PCI procedure, the patient was admitted to Intensive Cardiac Care Unit (ICCU) for further close monitoring and treatment.

In ICCU, the patient was given acetosal 100 mg once daily and ticagrelor 90 mg twice daily. Anticoagulation therapy was administered with subcutaneous enoxaparin 0.4 mL once daily. In addition, eptifibatid infusion was administered at a maintenance rate of 11 mL/hour for 24 hours after the procedure.

Patient was also given intravenous lansoprazole 30 mg once daily, while ondansetron 8 mg intravenously three times daily as needed was given for nausea and vomiting. Diuretic therapy included an initial bolus of furosemide 40 mg followed by continuous infusion at 2.5–5 mg/hour, along with intravenous furosemide 20 mg twice daily. Other medications included allopurinol 100 mg once daily, atorvastatin 80 mg once daily, bisoprolol 1.25 mg once daily with planned titration to 2.5 mg once daily, ramipril 2.5 mg once daily, ISDN 5 mg once daily, and spironolactone 12.5 mg once daily. Intravenous fluid therapy with 0.9% normal saline was administered at 40 mL/hour using an infusion pump.

Post-procedural care included femoral sheath monitoring, with femoral hemostasis planned for the following morning at 06:00 if activated partial thromboplastin time (aPTT) was within the normal range. Urine output was closely monitored with a target of 150 mL/hour for the first six hours after the procedure. Renal function tests (blood urea nitrogen and serum creatinine) were scheduled to be reassessed 12 hours after rehydration. Continuous monitoring for symptoms, vital signs, cardiac markers, and any signs of bleeding was also performed. After two days of treatment in ICCU, the patient can be transferred to the cardiac unit.

In the cardiac unit, the patient complaint about the shortness of breath and he said the complaint was improving until the sixth day of hospitalization. Patient still continue his treatment,

including intravenous fluid therapy with 0.9% sodium chloride administered at 8 drops per minute, cetosal 100 mg once daily, ticagrelor 90 mg twice daily, enoxaparin 0.4 IU once daily was continued until day 3–5, ramipril 2.5 mg twice daily, isosorbide dinitrate (ISDN) 5 mg three times daily, and bisoprolol titrated up to 2.5 mg twice daily, intravenous furosemide 20 mg twice daily, along with spironolactone 12.5 mg once daily. The patient also received intravenous lansoprazole 30 mg once daily for gastric protection. Laxadine was administered as needed to prevent constipation. On the sixth day of hospitalization, the patient had a stable condition and was discharged from the hospital.

## **Discussion**

This case underscores an extensive anterior STEMI in a 30-year-old male patient (Ferrante et al., 2021; Satrijo, 2022). The patient undergoes several procedures, such as history taking, clinical examinations, and additional examinations, such as ECG examination, laboratory investigations, X-ray imaging, and echocardiography. Furthermore, the patient was treated with primary PCI (Satrijo, 2022; Rao et al., 2025).

This patient came with the complaint of chest pain, and the pain was radiated to the back. The patient also had several additional examinations, such as ECG, laboratory examinations, and radiological examinations. This was in line with the previous studies that showed STEMI was a condition characterized by typical chest pain, with an elevation in the ST-segment in the 12-lead ECG (Elendu et al., 2023; Kumar & Cannon, 2009). Moreover, the patient also presented an increase in cardiac markers, such as high-sensitivity cardiac troponin (hs-troponin)/(hs-cTn), which exceeded the normal limit (Elendu et al., 2023). According to our case, the patient showed the elevation of the ST-segment in certain ECG leads, including V1 to V6 leads, which showed the appearance of ST-segment elevation in the extensive anterior area. Moreover, the patient had a high hs-troponin marker, which confirmed the diagnosis of extensive anterior STEMI (Ferrante et al., 2021). Our patient also underwent echocardiography and coronary angiography as additional advanced imaging modalities. The coronary angiography showed that the patient had a high thrombus burden. This patient is a male who is 30 years old. Although STEMI often occurs in older patients, there was an epidemiological transition recently which showed an increasing of STEMI diagnoses in young patients (Nantumbwe et al., 2025). Previous studies that analyzed patients who had STEMI under 45 years old showed that the patients were predominantly male gender and had smoking habits (Nantumbwe et al., 2025).

Patient received initial treatment in the department, such as ISDN and loading dose of dual antiplatelet (acetosal and clopidogrel). The patient also received enoxaparin, atorvastatin, ramipril, and lansoprazole, and was advised to undergo primary PCI (Kardiovaskular PDS, 2024; Rao et al.,

2025). These treatment modalities were in line with the previous studies that analyzed the treatment in STEMI patients. The STEMI management is evolving from time to time, with the emphasis on early reperfusion therapy and adjunctive pharmacological interventions, which both aim to reduce the myocardial damage and also improve the clinical outcomes in the patients (Kardiovaskular PDS, 2024; Rao et al., 2025).

The dual antiplatelet therapy—particularly, aspirin and oral P2Y12 inhibitors—was specifically aimed at reducing the risk of recurrent thrombotic events. Aspirin has been demonstrated to lower the risk of vascular mortality following acute myocardial infarction (AMI) (Kumar & Cannon, 2009; Rao et al., 2025). In the context of secondary prevention, including post-MI populations, aspirin also reduces the incidence of major vascular and coronary events such as recurrent myocardial infarction and stroke (Kumar & Cannon, 2009). In addition, oral P2Y12 receptor inhibitors act by blocking adenosine diphosphate (ADP)–mediated platelet activation. Across the continuum of acute coronary syndromes (ACS), the addition of a P2Y12 inhibitor to aspirin enhances platelet inhibition and significantly decreases the risk of recurrent major adverse cardiovascular events (MACE), albeit at the expense of an increased bleeding risk (Rao et al., 2025). The selection of a specific oral P2Y12 inhibitor should be individualized, taking into account factors such as the intended treatment strategy and the patient’s bleeding risk profile. Currently available oral P2Y12 inhibitors include clopidogrel, prasugrel, and ticagrelor. Among these, clopidogrel is the least potent and has a slower onset of action, as it requires hepatic biotransformation to generate its active metabolite, thereby delaying maximal platelet inhibition following a loading dose (Kumar & Cannon, 2009).

In addition, other pharmacological interventions, such as anticoagulation (such as enoxaparin), ACE inhibitors (such as ramipril), and statins (such as atorvastatin), and proton-pump inhibitor (such as lansoprazole) were given to the patient, and this approach was in line with earlier studies (Kardiovaskular PDS, 2024; Rao et al., 2025). The anticoagulation medications can be given to the STEMI patients because its effect to prevent the clot formation and propagation during reperfusion therapy. Moreover, this medication was combined with the DAPT (Kardiovaskular PDS, 2024). Enoxaparin, one of the anticoagulations resulted significantly reduction of mortality and myocardial infarct in STEMI patients compared with unfractionated heparin (UFH) (Hai-long et al., 2018). According to the previous study, the angiotensin-converting inhibitor showed an efficacious effect in the early phase of STEMI, which attenuates ventricular remodeling, enhances cardiac function, and reduces the risk of subsequent heart failure (Kardiovaskular PDS, 2024). Several studies have demonstrated a statistically significant reduction in mortality. The greatest reduction in mortality rates was observed within the first five days following myocardial infarction,

highlighting the critical importance of early initiation of therapy (Kumar & Cannon, 2009). Statins were known as one of the pharmacological approaches that can be administered to the STEMI patients. According to the guideline, statins were recommended to be given to the STEMI patients to reduce the cholesterol levels and reduce the risk of recurrent cardiovascular events (Kardiovaskular PDS, 2024). Pre-procedural administration of high-dose statins may be considered in patients with STEMI undergoing primary percutaneous coronary intervention (PPCI). This strategy has been shown to improve post-procedural myocardial perfusion, as reflected by enhanced Thrombolysis in Myocardial Infarction (TIMI) flow, and to reduce the incidence of major adverse cardiovascular events (MACE) (Satrijo, 2022). In addition, an earlier study showed the administration of PPI (lansoprazole) combined with the DAPT can reduce gastrointestinal events without adversely affecting cardiovascular outcomes in patients with the coronary intervention (Liang et al., 2023). The addition of a PPI confers a protective effect against gastrointestinal ulceration and upper gastrointestinal bleeding (Liang et al., 2023).

The primary PCI, particularly the Plain old balloon angioplasty (POBA) with deferred stenting, was performed in our patient. To date, plain old balloon angioplasty (POBA) remains efficacious in selected patients who are unable to tolerate prolonged dual antiplatelet therapy, as well as in anatomically complex lesions involving small-caliber coronary vessels where stent implantation is not feasible (Her et al., 2016). The POBA demonstrated higher target vessel revascularization compared with the paclitaxel-coated balloon in stable or unstable angina patients who underwent PCI (Her et al., 2016). The principle of myocardial infarct management is to relieve the pain through reperfusion therapy. These interventions consist of two ways, including primary PCI and thrombolytic therapy (Kumar & Cannon, 2009). Reperfusion therapy should be performed as early as possible after the onset of symptoms to preserve the ischemic myocardium. Furthermore, the reported studies showed early thrombolytic administration, particularly within 12 hours of symptom onset, has been shown to reduce mortality in myocardial infarction (Wahyudi & Gani, 2019).

Primary percutaneous coronary intervention (PCI) targeting the infarct-related artery (IRA) remains the gold standard for reestablishing myocardial perfusion and minimizing infarct size in patients with STEMI (Satrijo, 2022). The implantation of stents is widely performed to provide mechanical stabilization of atherosclerotic plaques and to reduce the risk of acute occlusion and restenosis (Rao et al., 2025). However, in this case, our patient had a high thrombus burden (HTB) condition that was detected through angiography, primary PCI with POBA, and deferred stenting was performed. This was in line with the previous study, the deferred stenting was considered as one of the treatment approaches that allows for thrombus reduction to be achieved through the pharmacological interventions (Pradhan et al., 2021). Furthermore, the earlier study showed that

significant complete thrombus resolution was observed more frequently in the deferred stenting group than in the immediate stenting group (83 [83%] vs. 67 [67%],  $p=0.01$ ) and significant improvement of LVEF in the deferred stenting group compared with the immediate stenting group ( $p<0.001$ ) (Qiao et al., 2017). According to the previous study, deferred stenting also showed an increased rate of procedural success, and decreased of adverse events compared with immediate stenting (Hammad et al., 2025). Other studies that compared deferred stenting and immediate stenting showed that there was decreased of thrombus burden during the second PCI in the deferred stenting group, while the severity of residual stenosis was lower compared with the immediate stenting group (Sakellariou et al., 2021). Notably, in three patients within the deferred stenting cohort who exhibited stenosis of  $<50\%$ , stent implantation was not performed (Sakellariou et al., 2021). The immediate stenting can increase the risk of no reflow and leads to microvascular obstruction. The no-reflow condition is typically characterized by reduced TIMI flow in the culprit artery after stent implantation, resulting in impaired myocardial perfusion despite adequate epicardial coronary flow (Hammad et al., 2025).

Our study showed the case of a patient with STEMI and HTB who was treated with primary PCI, particularly POBA and deferred stenting. After the procedures, the patient showed a better clinical outcome compared with the first time when he was admitted to the emergency department and was advised to continue the pharmacological interventions.

## **Conclusion**

The early diagnosis of STEMI is required to give an earlier and adequate treatment to the patients and, furthermore, to give better clinical outcomes to the patients. The primary PCI still remains considered as a gold standard for reestablishing myocardial perfusion and minimizing infarct size in patients with STEMI. However, in certain conditions, such as high thrombus burden (HTB), the immediate implantation of stenting may give a higher risk of no reflow. Therefore, the primary PCI with POBA and deferred stenting can be considered as an alternative treatment approaches in STEMI with HTB patients. Acknowledgment

## **Acknowledgements**

The authors would like to thank the medical and nursing staff involved in the care of the patient for their assistance in data collection. No external funding was received for this study.

## References

- Laksono S, Nurbaeti P. Clinical and Demographic Characteristics of Patients with ST-Elevation Myocardial Infarction in Siloam Heart Center : A Single Center Study. *J Indon Med Assoc.* 2025;75(3):148–55.
- Kardiovaskular PDS. Pedoman Tata Laksana Sindrom Koroner Akut. 2024.
- Ferrante G, Barbieri L, Sponzilli C, Lucreziotti S, Uriarte DS, Centola M, et al. Predictors of Mortality and Long-Term Outcome in Patients with Anterior STEMI : Results from a Single Center Study. *J Clin Med.* 2021;10(5634):1–11.
- Pradhan A, Bhandari M, Vishwakarma P, Sethi R. Deferred Stenting for Heavy Thrombus Burden During Percutaneous Coronary Intervention for ST-Elevation MI. *Eur Cardiol Rev.* 2021;16(e08):1–7.
- Nantumbwe SN, Gardiner R, Kiernan TJ, Cummins NM. Risk factors associated with ST - segment elevation myocardial infarctions among young patients treated in the Mid - West of Ireland : a case series report using secondary data. *Irish J Med Sci (1971 -)* [Internet]. 2025;194:1267–77. Available from: <https://doi.org/10.1007/s11845-025-03965-w>
- Elendu C, Amaechi DC, Elendu TC, Omeludike EK, Alakwe-ojimba CE, Obidigbo B, et al. Comprehensive review of ST-segment elevation myocardial infarction: Understanding pathophysiology, diagnostic strategies, and current treatment approaches. *Medicine (Baltimore).* 2023;102(43):1–7.
- Rao S V., O'Donoghue ML, Ruel M, Rab T, Tamis-Holland JE, Alexander JH, et al. 2025 ACC / AHA / ACEP / NAEMSP / SCAI Guideline for the Management of Patients With Acute Coronary Syndromes : A Report of the American College of Cardiology / American Heart Association Joint Committee on Clinical Practice Guidelines. 2025. 1–92 p.
- Hai-long W, Xiao-hua P, Jian-jun Y. The efficacy and safety of enoxaparin: a meta-analysis. *gruyter Open Med.* 2018;13:359–65.
- Kumar A, Cannon CP. Acute Coronary Syndromes: Diagnosis and Management , Part II. *Symp Cardiovasc Dis.* 2009;84(November):1021–36.
- Satrijo B. The Current Perspective of Primary Percutaneous Coronary Intervention for ST-Elevation Myocardial Infarction Patients. *Hear Sci J.* 2022;3(February):1–2.
- Liang S, Ma M, Chen Y, Zhang J, Li J, Jiang S, et al. The Efficacy and Safety of Proton Pump Inhibitors Combining Dual Antiplatelet Therapy in Patients with Coronary Intervention : A Systematic Review , Meta-Analysis and Trial Sequential Analysis of Randomized Controlled Trials. *Rev Cardiovasc Med.* 2023;24(8):1–11.
- Her A, Ann SH, Singh GB, Kim YH, Yoo S, Garg S, et al. Comparison of Paclitaxel-Coated Balloon Treatment and Plain Old Balloon Angioplasty for De Novo Coronary Lesions. *Yonsei Med J.* 2016;57(2):337–41.
- Wahyudi H, Gani A. Keberhasilan Tatalaksana ST Elevation Myocardial Infarction ( STEMI ) dengan Streptokinase. *J Kedokt Nanggroe Med.* 2019;2(2):33–8.
- Hammad AH, Ismaiel MA, Abd-elnaby MH, Taha AK, Kabil H. Deferred Versus Immediate Stenting in Late- Presenting ST-Segment Elevation Myocardial Infarction ( STEMI ) Patients With a High Thrombus Burden : A Retrospective Analysis. *Cureus.* 2025;17(6):e86317.
- Qiao J, Pan L, Zhang B, Wang J, Zhao Y, Yang R, et al. Deferred Versus Immediate Stenting in Patients With ST-Segment Elevation Myocardial Infarction: A Systematic Review and Meta-Analysis. *J Am Heart Assoc.* 2017;6(e004838):1–13.
- Sakellariou XM, Katsanos GI, Efstathopoulos AP, Sfairopoulos DG, Stamatis K V, Pappas SD, et al. Should Deferred Stenting Still Be Considered in ST-Elevation Myocardial Infarction with High Thrombus Burden ? *J Cardiovasc Dev Dis.* 2021;8(59):2–5.